

THE QUEENSLAND JOURNAL OF AGRICULTURAL SCIENCE

VOL. 10. - - No. 3.
SEPTEMBER, 1953.

FLOCK MANAGEMENT TO CONTROL FLUOROSIS OF MERINO SHEEP IN QUEENSLAND.

By J. M. HARVEY, M.Sc., Senior Chemist, Biochemical Section, Chemical Laboratory,
Division of Plant Industry.

SUMMARY.

An investigation was made to determine how fluorosis in Merino sheep could be alleviated by variations in the time of exposure to and protection from fluorided water. The treatments used were considered in relation to field application under Queensland conditions.

Eighty Merino lambs, in four equal groups, were subjected to the following treatments for 30 months from three months of age:—

Group 1—Continuously exposed to fluorided water.

Group 2—Alternately exposed to and protected from fluorided water for periods of three months.

Group 3—Alternately exposed for six months to and protected for three months from fluorided water.

Group 4—Alternately exposed to and protected from fluorided water for periods of six months.

The animals were kept in small paddocks and their diet was grassy lucerne hay fed in bales together with limited grazing. The fluorided water was prepared to contain 10 p.p.m. F.

Liveweight gains and wool growth were comparable in all groups.

No abnormalities in femur, tibia or mandible were detected.

The lesions of fluorosis were apparent in the incisor teeth of all sheep but were least pronounced in the group alternately exposed to and protected from fluorine for periods of three months. The fluorine concentration in bones and teeth was also least in this group.

As a result of this study, together with findings recorded previously by the author, a system of flock management is recommended. The system is based on the presence or provision of alternative fluorine-free water, but enables the maximum use of fluorided water with the minimum of damage to sheep.

INTRODUCTION.

In an earlier publication (Harvey, 1952) it was stated that in the light of present knowledge the only means of ameliorating chronic endemic fluorosis of Merino sheep in Queensland is by flock management. This conclusion was based on observations on affected properties, where efficient management and the use of fluorine-free water for sheep during their susceptible period were found to reduce fluorotic symptoms greatly.

The object of the investigation now reported was to determine how fluorosis in sheep might be alleviated by variation in the time of exposure to and protection from water containing fluorine.

EXPERIMENTAL.

The experimental animals were Merino lambs three months of age at the beginning of the experiment. They were bred on a property in south-western Queensland from ewes which had not been exposed to water containing fluorine. A uniform line of 80 lambs was selected from 100 brought to Yeerongpilly, and they were divided into four equal groups which were treated as follows:—

Group 1—Continuously on water containing 10 p.p.m.F.

Group 2—Alternately for 3 months on water containing 10 p.p.m.F. and 3 months on fluorine-free water.

Group 3—Alternately for 6 months on water containing 10 p.p.m.F. and 6 months on fluorine-free water.

Group 4—Alternately for 6 months on water containing 10 p.p.m.F. and 3 months on fluorine-free water.

Two paddocks of approximately an acre each were used. In one paddock the sheep had access to water containing less than 0.1 p.p.m.F. In the other paddock the complete drinking supply contained 10 p.p.m.F. This drinking water was prepared in 44-gallon drums by the addition and thorough mixing of the required amount of sodium fluoride. Analyses were made at regular intervals to ensure that the desired concentration of 10 p.p.m.F. was maintained. The 44-gallon storage tanks and the drinking troughs were protected from sun and rain to minimise changes in concentration.

The diet was grassy lucerne hay of poor quality fed in bales. Limited grazing was also available, but this was not extensive, as each paddock averaged approximately 40 sheep to the acre.

All sheep were given anthelmintic treatment with phenothiazine at the commencement and at monthly intervals during the course of the study.

Liveweights and observations on the incisor teeth were recorded at monthly intervals.

The duration of the investigation was 30 months. Six animals from each group were then autopsied. Photographs of the incisor teeth were taken and X-ray plates of the femur, tibia and mandible were made. Kidney, femur, tibia, mandible and incisor, molar and premolar teeth were analysed for fluorine.

The design of the investigation was based on the following considerations:—

- (1) Any one of the ameliorative treatments is practicable in endemic areas. On an affected property there may be one or more fluorine-free bores; alternatively, there may be, or could be constructed, earth tanks for the trapping of surface water.
- (2) The high level of fluorine (10 p.p.m.F) corresponds with that of badly affected water. This level can occur at the borehead or, more commonly, at a distant portion of a long drain where concentration by evaporation has considerably increased the fluorine content. If any of the systems of intermittent exposure showed beneficial effects in comparison with the continuously exposed group, such effects would be enhanced under less severe conditions.
- (3) The use of 3-month-old lambs enabled all groups to be exposed to fluorided water during the period immediately prior to or immediately after early weaning. The systems of management were therefore compared under severe conditions of exposure to affected water.
- (4) The rate of stocking of the paddocks meant that the bulk of the diet had to come from the grassy lucerne hay fed in bales. This was arranged to simulate the wear on teeth that occurs under field conditions in endemic areas.

RESULTS.

Tables 1-4 record the observations on the incisor teeth of the sheep in each group. The inspections were made at monthly intervals, so the comments denote the onset of symptoms of fluorosis as judged by damage to the permanent incisors. At the conclusion of the investigation, when the sheep were 33 months of age, all except one sheep had erupted the third pair of incisors and a number had erupted the fourth pair. The severity of the fluorotic lesions on incisor teeth was used to compare treatments.

The mean monthly weights for each group are shown in Fig. 1.

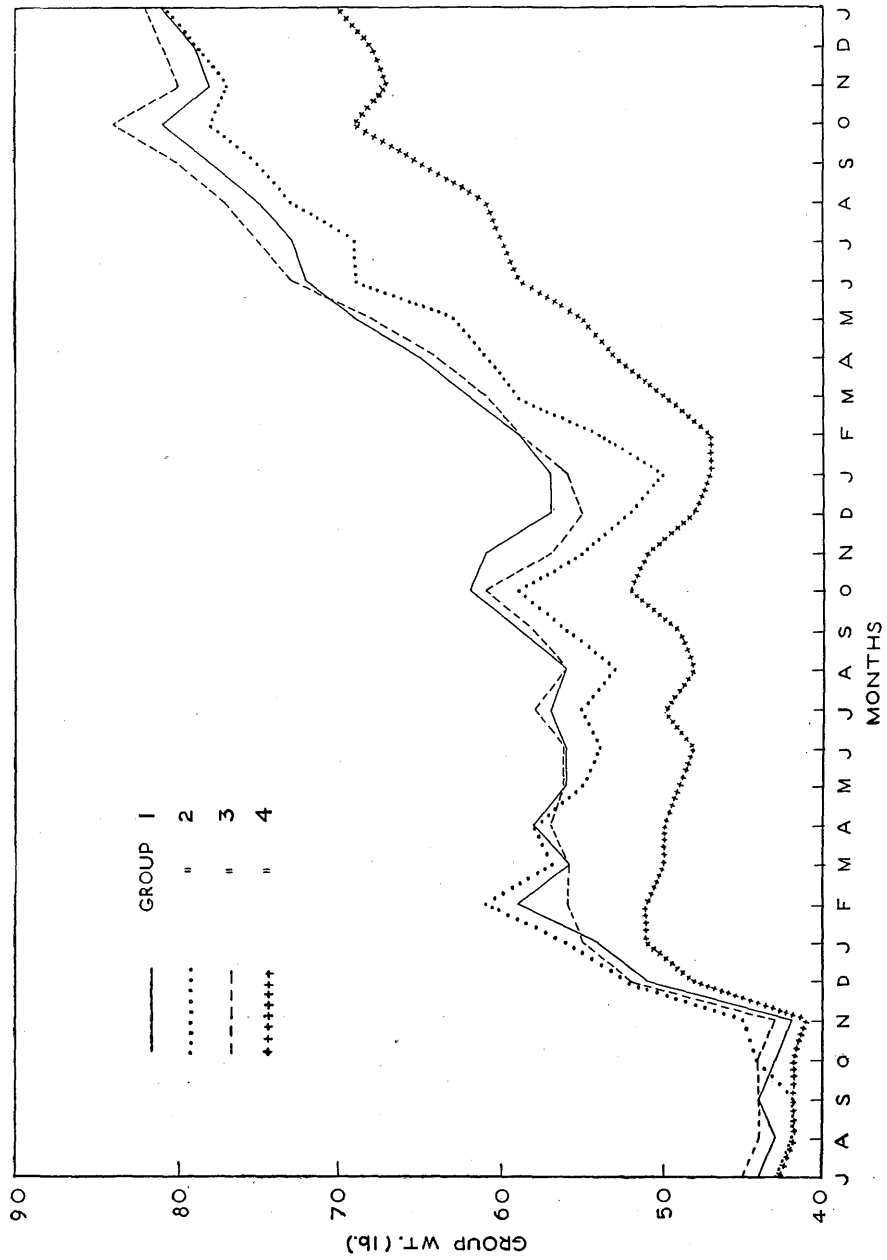


Fig. 1.
Graph Showing Mean Monthly Weight of Sheep in Each Group.

Table 1.
OBSERVATIONS ON INCISOR TEETH OF SHEEP FROM GROUP 1.
(Continuously Exposed Group.)

Age (Months).	Observations.	
	Eruption of Incisors.	Fluorotic Lesions.
3—9	Deciduous teeth only.	
10	1st pair erupting in four sheep.	
11	1st pair in seven sheep.	Overlapped in three sheep; all show erosion, fine chalky striations and chalky spots, staining and some deep pitting.
12	1st pair in nine sheep.	Erosion and chalky striations more pronounced.
13	1st pair in all except three sheep.	Some chipping of cutting surfaces as teeth come into wear.
14	1st pair in all sheep.	Marked chalky striations, erosion and some deep pitting; staining more pronounced; some chipping.
15	1st pair in all sheep.	Increased wear on cutting surfaces.
16	2nd pair erupting in two sheep.	No change.
17	2nd pair in three sheep.	Paper white; deeply eroded, with pronounced chalky bands.
18	2nd pair in eight sheep.	Erosion and chalky striations more pronounced than in 1st pair.
19	2nd pair in all except four sheep.	One deformed incisor arch.
20	2nd pair in all except four sheep.	No change.
21	2nd pair in all except two sheep.	Markedly striated and some chipping; increased wear on 1st pair.
22	3rd pair erupting in two sheep.	No change.
23	2nd pair in all sheep; 3rd pair in two sheep.	All incisors show marked evidence of fluorosis.
24	3rd pair in seven sheep.	All markedly striated, with chalky bands.
25	3rd pair in seven sheep.	No change
26	3rd pair in all except four sheep.	All show marked striations developing to chalky areas; 2nd pair show chalky bands with erosion and pitting to give horizontal lines of weakness; 1st pair show striations and erosion more pronounced in the lower half.
27	3rd pair in all except four sheep.	No change.
28	3rd pair in all except one sheep; 4th pair erupting in two sheep.	No change.
29	3rd pair in all sheep; 4th pair in four sheep.	No change.
30	4th pair in seven sheep.	4th pair deeply eroded and markedly striated; 3rd pair eroded, with some deep pitting and pronounced chalky bands; 2nd pair similar to 3rd pair but cutting surfaces are more worn; 1st pair badly worn, markedly striated over the lower half, with some deep lines of pitting at the gum margin.

Table 2.

OBSERVATIONS ON INCISOR TEETH OF SHEEP FROM GROUP 2.
(Three Months' Exposure and Three Months' Protection.)

Age (Months).	Observations.	
	Eruption of Incisors.	Fluorotic Lesions.
3—9	Deciduous teeth only.	
10	1st pair erupting in one sheep.	
11	1st pair in two sheep.	Fine transverse striations with slight staining.
12	1st pair in six sheep.	Erosion with fine striations and slight staining.
13	1st pair in 12 sheep.	Slight chipping of cutting surfaces.
14	1st pair in all except two sheep	Erosion marked in two sheep only.
15	1st pair in all except one sheep.	Fine striations and some chalky spots ; some chipping.
16	1st pair in all except one sheep.	No change.
17	1st pair in all sheep ; 2nd pair erupting in three sheep.	No change.
18	2nd pair in four sheep.	Fine striations with some erosion.
19	2nd pair in seven sheep.	1st pair show increased wear on cutting surfaces.
20	2nd pair in 11 sheep.	No change.
21	2nd pair in all except three sheep ; 3rd pair erupting in one sheep.	All incisors show fine striations and some erosion emphasised by staining ; 1st pair show wear.
22	2nd pair in all except three sheep ; 3rd pair erupting in one sheep.	No change.
23	2nd pair in all sheep ; 3rd pair in two sheep.	One deformed incisor arch.
24	3rd pair in five sheep.	All incisors tend to be paper white, with fine striations, erosion and staining.
25	3rd pair in five sheep.	No change.
26	3rd pair in seven sheep.	In only three sheep are there evident lesions of fluorosis ; all other sheep in this group are classed as mild cases at this stage.
27	3rd pair in all except six sheep.	No change.
28	3rd pair in all except four sheep ; 4th pair erupting in one sheep.	No change.
29	3rd pair in all except one sheep ; 4th pair erupting in two sheep.	A deformed incisor arch in two sheep ; increased wear on 1st pairs.
30	3rd pair in all sheep ; 4th pair in three sheep.	Three sheep show marked striations with erosion and some deep pitting on 2nd and 3rd pairs ; other sheep in this group show fine striations and mild erosion, with some wear on cutting surfaces.

Table 3.
OBSERVATIONS ON INCISOR TEETH OF SHEEP FROM GROUP 3.
(Six Months' Exposure and Three Months' Protection.)

Age (Months).	Observations.	
	Eruption of Incisors.	Fluorotic Lesions.
3—8	Deciduous teeth only.	
9	1st pair erupting in four sheep.	
10	1st pair in nine sheep.	All show erosion and marked chalky striations.
11	1st pair in 12 sheep.	As at 10 months plus slight chipping of cutting surfaces.
12	1st pair in all except five sheep.	Marked erosion, pronounced tranverse chalky bands, some staining and chipping.
13	1st pair in all except one sheep.	Some deep pitting, increased wear on cutting surfaces.
14	1st pair in all except one sheep.	No change.
15	2nd pair erupting in two sheep.	No change.
16	1st pair in all sheep ; 2nd pair in six sheep.	Paper white, markedly striated, with chalky areas, deeply eroded and 1st pair badly worn ; one deformed incisor arch.
17	2nd pair in 12 sheep.	No change.
18	2nd pair in all except four sheep.	No change.
19	2nd pair in all except three sheep.	As before plus increased wear on 1st pair.
20	2nd pair in all except two sheep.	No change.
21	2nd pair in all except one sheep ; 3rd pair erupting in four sheep.	No change.
22	2nd pair in all sheep ; 3rd pair in six sheep.	All markedly eroded, striated and stained ; 2nd pair show some deep bands of pitting, pronounced chalky areas and increased wear on cutting surfaces.
23	3rd pair in 10 sheep.	No change.
24	3rd pair in all except six sheep.	Marked chalky bands and chalky areas, some deep pitting.
25	3rd pair in all except six sheep.	No change.
26	3rd pair in all except four sheep ; 4th pair erupting in one sheep.	All incisors show marked fluorotic lesions and closely resemble those in sheep from group 1 ; vertical cracks are apparent in the cutting surfaces of 1st and 2nd pairs.
27	3rd pair in all except three sheep ; 4th pair in one sheep.	No change.
28	3rd pair in all except two sheep ; 4th pair in six sheep.	One 1st incisor broken at line of pitting.
29	3rd pair in all except one sheep ; 4th pair in 11 sheep.	No change.
30	3rd pair in all sheep ; 4th pair in all except five sheep.	All incisors show marked evidence of fluorosis ; 1st pair broken in two sheep ; four sheep have a deformed incisor arch.

Table 4.
OBSERVATIONS ON INCISOR TEETH OF SHEEP FROM GROUP 4.
(Six Months' Exposure and Six Months' Protection.)

Age (Months).	Observations.	
	Eruption of Incisors.	Fluorotic Lesions.
3—9	Deciduous teeth only.	
10	1st pair erupting in two sheep.	
11	1st pair in seven sheep.	All show erosion, fine chalky striations and slight staining.
12	1st pair in all except three sheep.	No change.
13	1st pair in all except one sheep.	All show erosion, pitting and chalky bands.
14	1st pair in all except one sheep.	No change.
15	1st pair in all sheep.	As before plus increased wear on cutting surfaces.
16	1st pair in all sheep.	No change.
17	2nd pair erupting in three sheep.	No change.
18	2nd pair in six sheep.	All show erosion and chalky striations; some deep pitting on 1st pair and worn cutting surfaces; one deformed incisor arch.
19	2nd pair in six sheep.	No change.
20	2nd pair in all except four sheep.	Increased wear on 1st pair.
21	2nd pair in all except three sheep.	No change.
22	2nd pair in all sheep.	Eroded, with some deep pitting, finely striated, with chalky bands in three sheep.
23	3rd pair erupting in three sheep.	No change.
24	3rd pair in four sheep.	Eroded, striated and stained.
25	3rd pair in five sheep.	No change.
26	3rd pair in all except six sheep.	The fluorotic lesions are more marked in this group than in group 2, but less severe than in groups 3 and 1.
27	3rd pair in all except three sheep.	No change.
28	3rd pair in all except three sheep.	No change.
29	3rd pair in all except two sheep; 4th pair in four sheep.	No change.
30	3rd pair in all except one sheep; 4th pair in four sheep.	All incisors are eroded and finely striated, with chalky bands in three sheep; some wear on cutting surfaces of 1st and 2nd pairs; one deformed incisor arch.

Table 5 records the fluorine concentration in kidney, femur, tibia, mandible, and incisor, premolar and molar teeth. The analyses were made on specimens from six sheep from each group taken after autopsy at 33 months of age, and the fluorine levels reported are the means of the six determinations for each of the groups.

Table 5.

FLUORINE CONCENTRATION IN KIDNEY, BONES AND TEETH.
(p.p.m.F on Dry Matter Basis, Fat-free Bones and Teeth.)

Group No.	Sheep No.	Tissue.										
		Kidney.	Femur.	Tibia.	Mandible.	1st pair.	2nd pair.	3rd pair.	4th pair.	3rd pre-molar.	2nd molar.	3rd molar.
1	1	100	2400	1840	2800	1400	1600	1500	1450	1760	1280	1520
	2	16	2080	1280	2960	960	1400	1350	1600	1400	1120	1280
	3	16	2640	1680	2960	1480	1760	1650	1600	1600	1440	1680
	4	24	2000	1440	2720	1120	1600	1520	1450	1360	1360	1360
	5	24	2000	1680	2720	1520	1200	1250	1300	1480	1520	1480
	6	10	2240	1760	3280	1680	1440	1420	1800	1520	1440	1440
	Mean		32	2227	1613	2907	1360	1500	1448	1533	1520	1360
2	1	52	1280	1040	1520	880	640	850	850	1040	880	1040
	2	12	1080	1000	1200	560	560	650	600	840	800	800
	3	16	1440	960	1360	680	760	800	700	800	720	720
	4	10	880	720	920	600	560	650	650	720	500	680
	5	10	1280	1040	1520	680	760	730	..	840	720	840
	6	16	1200	800	1120	720	800	720	620	720	800	640
	Mean		19	1193	927	1273	687	680	733	684	827	737
3	1	56	2080	1360	2320	1040	1120	1200	1700	1200	1160	1240
	2	10	1840	1200	2150	1240	1440	900	1400	1360	1240	1040
	3	10	2160	1840	2240	1120	1240	1100	1080	1320	720	1200
	4	10	1520	1040	2080	1330	960	900	1400	1040	960	880
	5	24	2080	1600	2160	1280	1360	1140	1200	1360	1400	1560
	6	28	1920	1440	2320	1320	1680	1750	1500	1120	1280	1520
	Mean		23	1933	1413	2212	1225	1300	1165	1380	1233	1127
4	1	20	1520	880	1600	920	880	700	..	840	840	880
	2	12	1200	880	1680	960	1200	1000	1600	1000	1000	1080
	3	12	1520	1040	1480	920	720	700	1100	720	1080	680
	4	10	1520	800	1600	750	760	1000	1000	840	840	720
	5	20	1680	1280	1680	1000	920	900	1200	960	680	880
	6	24	1440	1040	1600	800	640	750	1100	720	1200	880
	Mean		16	1480	987	1607	892	853	842	1200	847	940

Photographs of the incisor teeth of six sheep from each group taken after autopsy are shown in Figs. 2-5.

Fig. 2 shows the left half of the incisor arch of sheep from group 1. The changes in tooth structure, described as transverse chalky striations, were apparent in all specimens from this group, but such lesions are not clearly defined in photographic reproductions. Some deep pitting is apparent and is emphasised by staining. Splaying of the incisors is noticeable in sheep 2; sheep 5 and 6 show marked crowding with the 4th pair of incisors erupted at right angles. Some chipping of the cutting surfaces of the 1st pair can be seen in sheep 1 and 5.

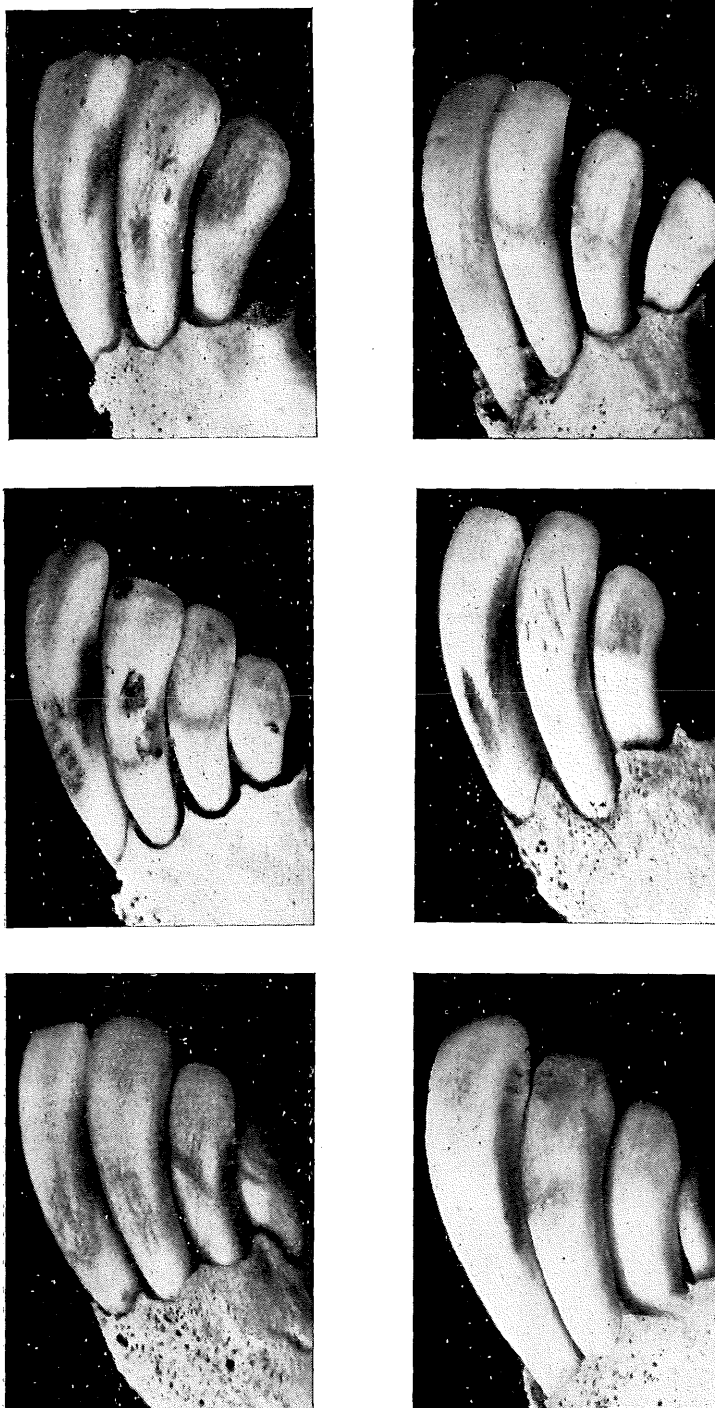


Fig. 2.
Left Half of the Incisor Arch of Sheep in Group 1.

Fig. 3 shows the left half of the incisor arch of sheep from group 2. Abnormalities in tooth structure are not readily apparent in animals from this group; chalky striations occurred but are not reproduced in the photographs. There has been some mottling, emphasised by staining. Chipping of the cutting surfaces is noticeable, and there are horizontal fractures close to the cutting edges. Erosion and pitting are less severe than in the other three groups.

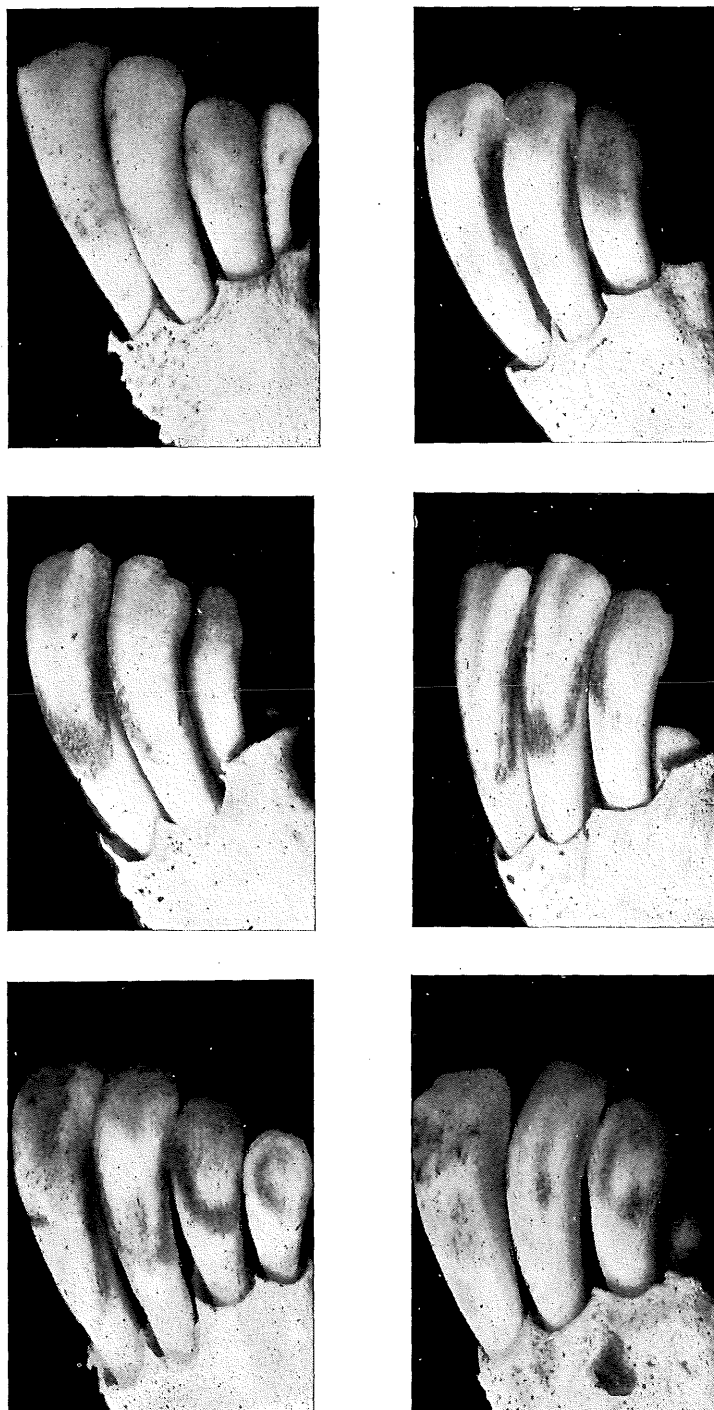


Fig. 3.

Left Half of the Incisor Arch of Sheep in Group 2.

Fig. 4 shows the left half of the incisor arch of sheep from group 3. Chalky striations may be discerned in each photograph. "Sheet" erosion and some deep pitting are emphasised by staining. Horizontal lines of weakness are indicated, and the 1st pair of incisors in sheep 1 have snapped off at one of the lines of weakness. Damage to the cutting surfaces is shown, particularly in sheep 1, 4 and 6.

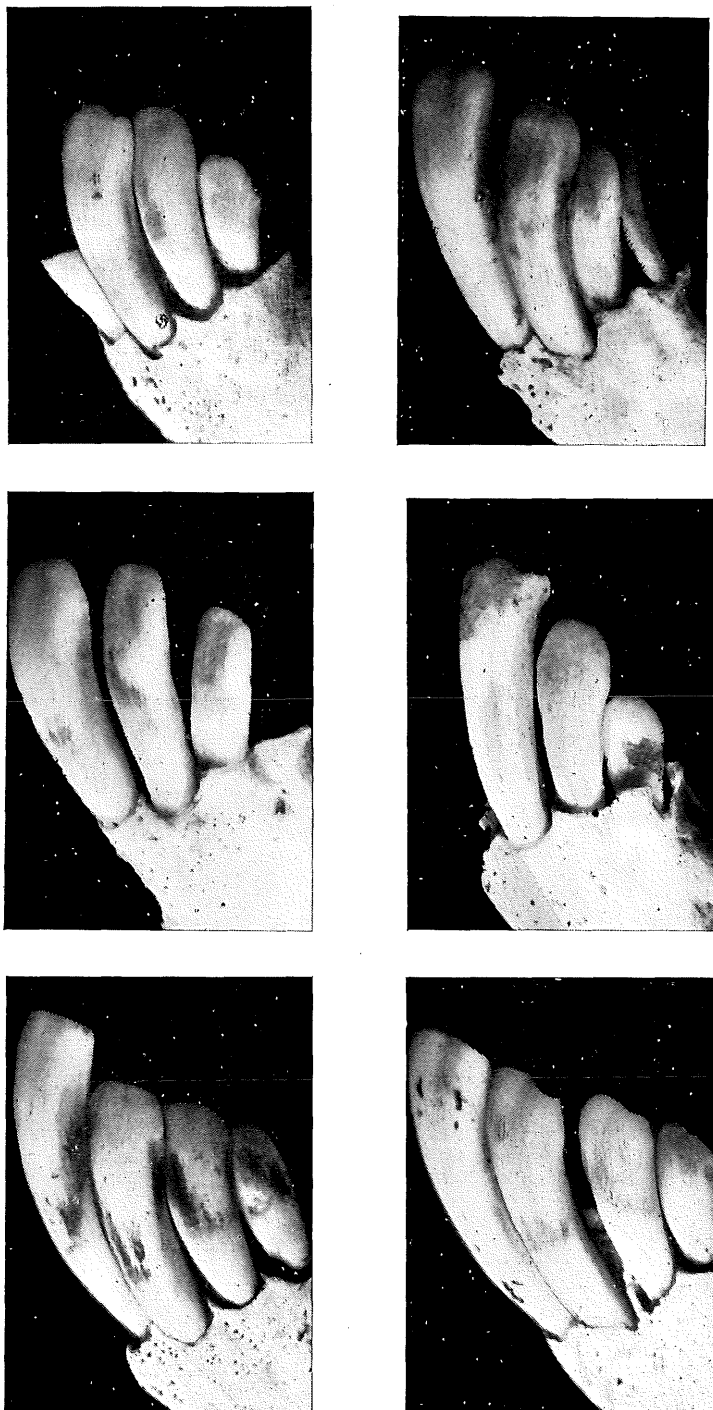


Fig. 4.

Left Half of the Incisor Arch of Sheep in Group 3.

Fig. 5 shows the left half of the incisor arch of sheep from group 4. Chalky transverse striations are apparent. Erosion and some deep pitting are emphasised by staining. Chipping of the cutting surfaces is noticeable in sheep 4, and there are some horizontal fractures towards the cutting edges.

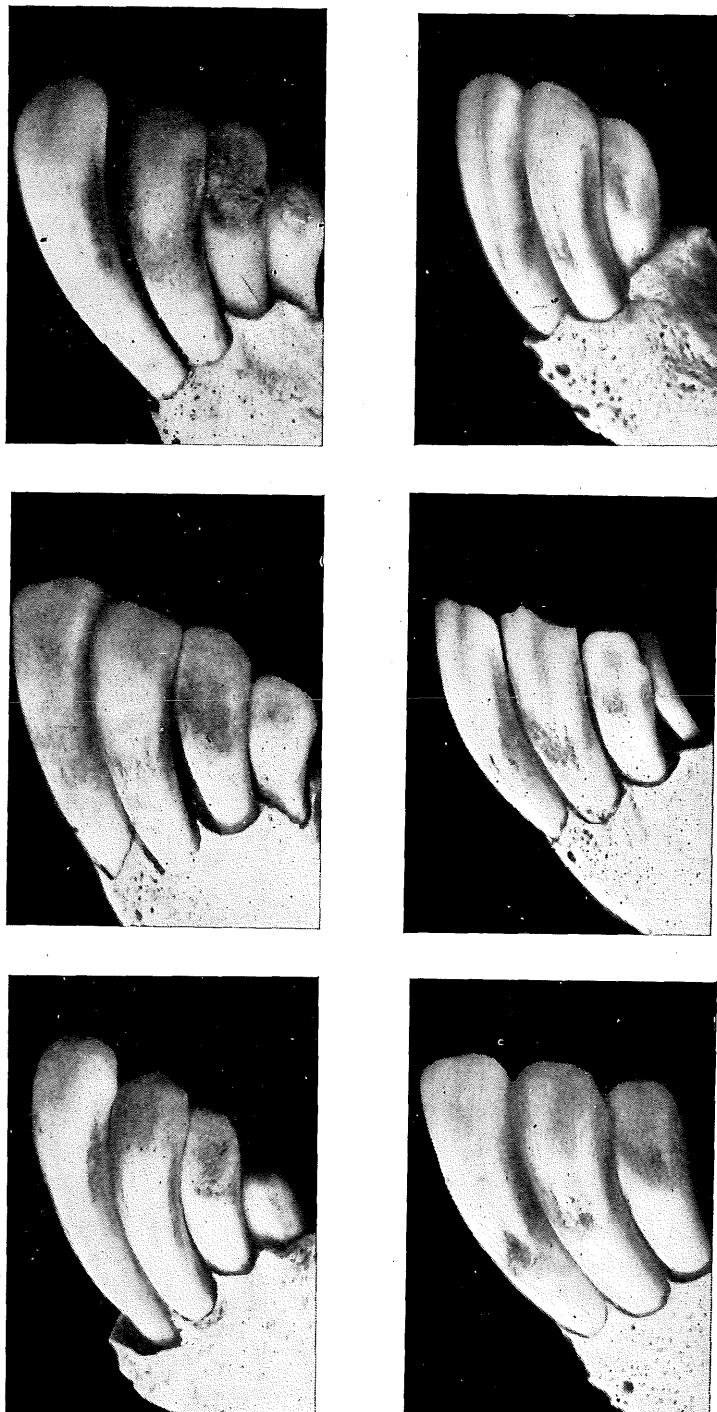


Fig. 5.

Left Half of the Incisor Arch of Sheep in Group 4.

X-ray photographs are shown in Figs. 6-29. These are of the mandible, femur and tibia of all animals slaughtered at the end of the investigation.

Figs. 6-11 show the mandible, femur and tibia of six sheep from group 1. In all cases there is good deposition of dense bone. There is some indication of uneven wear on molar and premolar teeth in four of the six photographs.

Figs. 12-17 show the mandible, femur and tibia of six sheep from group 2. No abnormalities are detectable.

Figs. 18-23 show the mandible, femur and tibia of six sheep from group 3. In four of the six photographs the dense bone appears thinner directly under the 3rd molar, and there is a tendency for the roots of this molar to extend into the compact substance. Some uneven wear on molar and premolar teeth is discernible in two photographs from this group.

Figs. 24-29 show the mandible, femur and tibia of six sheep from group 4. In two of the specimens some uneven wear of molar and premolar teeth is apparent.

DISCUSSION.

Examination of Tables 1-4 shows that fluorotic lesions were discernible in the incisor teeth of all the experimental animals. The severity of these lesions varied between animals within a group, but the variations were not large when compared with group differences. These findings support the following conclusions:—

- (1) The maximum damage was in group 1, the continuously exposed group.
- (2) The minimum damage resulted in group 2, the group alternately exposed and protected for periods of three months.
- (3) The lesions in group 3, the group alternately exposed for six months and protected for three months, closely resembled those in group 1.
- (4) The lesions in group 4, the group alternately exposed and protected for periods of six months, were intermediate in severity between those in group 3 and group 2.

The analytical data in Table 5 support the conclusion that, for these experimental animals, there is a relationship between fluorine storage in bones and teeth and the severity of the fluorotic lesions in incisor teeth. The maximum damage and the maximum fluorine storage occurred in the continuously exposed animals (group 1). The minimum damage and the minimum fluorine storage were found in group 2, the group alternately exposed and protected for periods of three months. The fluorine storage in bones and teeth in group 3, the group exposed for six months and protected

for three months, closely resembles that in group 1; the severity of the dental lesions in group 3 supports this finding. The fluorine levels in bones and teeth of sheep in group 4, the group alternately exposed and protected for periods of six months, are intermediate between those of group 3 and group 2. The fluorotic lesions in incisor teeth of group 4 are also intermediate in severity between those of group 3 and group 2.

Examination of the photographs of the incisor teeth at the end of the investigation support the conclusions drawn from the monthly examination of incisor teeth and the analytical data on fluorine storage in bones and teeth. The characteristic transverse chalky striations are not clearly depicted by monochrome photography but may be discerned in photographs of all groups other than group 2. Erosion and pitting are also less apparent in the photographs of specimens from group 2. Horizontal lines of weakness were present in the incisors from sheep in groups 1 and 3. This is emphasised in sheep 1 from group 3 (Fig. 4) in which the 1st incisor has snapped at a line of weakness. The only marked damage from exposure to fluorine of sheep in group 2 is the chipping and fractures at the cutting surfaces of incisor teeth. Such defects are also apparent in the incisor teeth of sheep in other groups.

The X-ray photographs of the mandible, femur and tibia (Figs. 6-29) do not indicate the bone rarification noted in previous studies (Harvey, 1952). There appears to have been a satisfactory deposition of dense bone in the femur and tibia of sheep of all groups. There is no indication of the shortening of the horizontal ramus of the mandible that was apparent in earlier studies. In four of the specimens from group 3 depicted in Figs. 18-23 the layer of dense bone tends to be thinner under the 3rd molar, and the roots of this molar extend into the compact substance. This abnormality was clearly evident in penned sheep exposed to drinking water containing fluorine during earlier investigations on the effect of dietary factors on the incidence of symptoms of fluorosis. There is no evidence of uneven wear on molar and premolar teeth in the specimens from group 2 depicted in Figs. 12-17, but there is an indication of uneven wear of teeth in some specimens illustrated in Figs. 6-11, 18-29.

In the previous studies and in this investigation, some groups were continuously exposed from the age of three months to drinking water containing 10 p.p.m.F. In the earlier studies the animals were housed in pens and fed chaffed or milled food. In the present investigation the animals were kept in small paddocks and had access to limited grazing plus hay fed in bales. The marked evidence of bone rarification in the former study and the equally strong evidence of normal bone deposition in the present investigation could be the effect of fluorine on sheep under different conditions of housing and feeding.

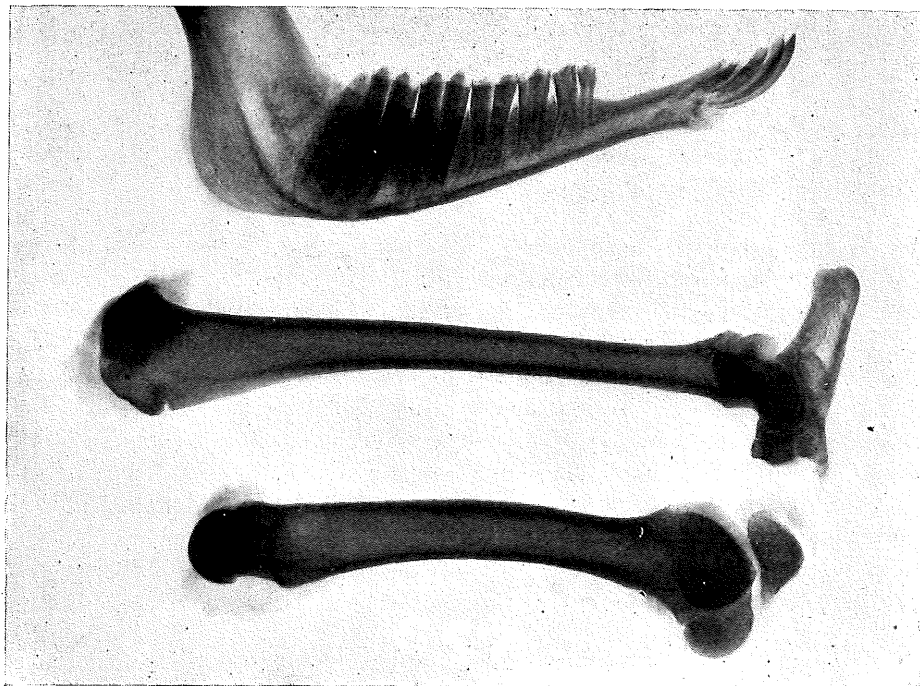


Fig. 6.

Mandible, Femur and Tibia of Sheep from Group 1.

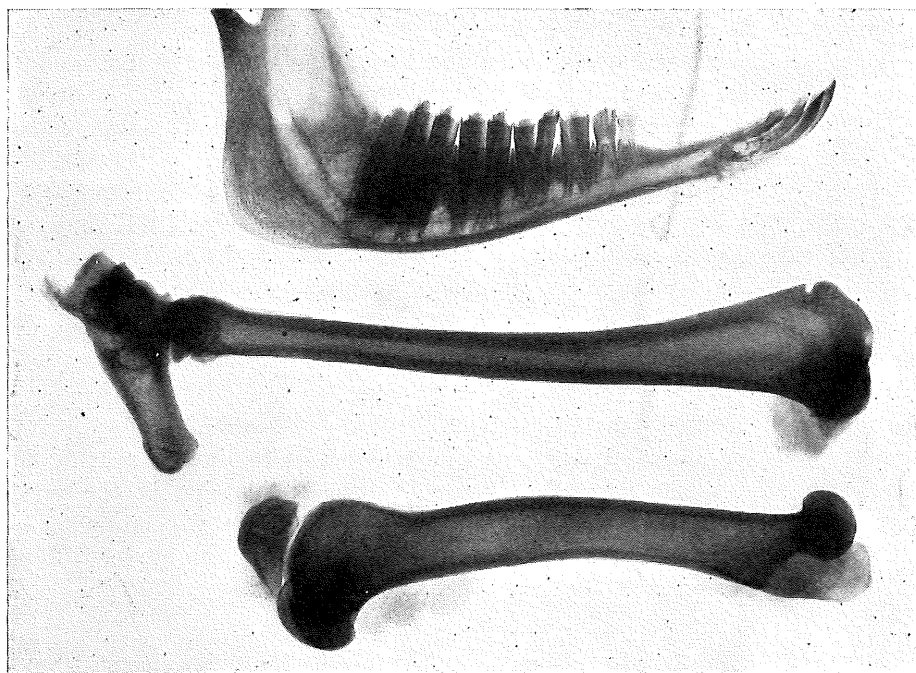

Fig. 7.

Mandible, Femur and Tibia of Sheep from Group 1.

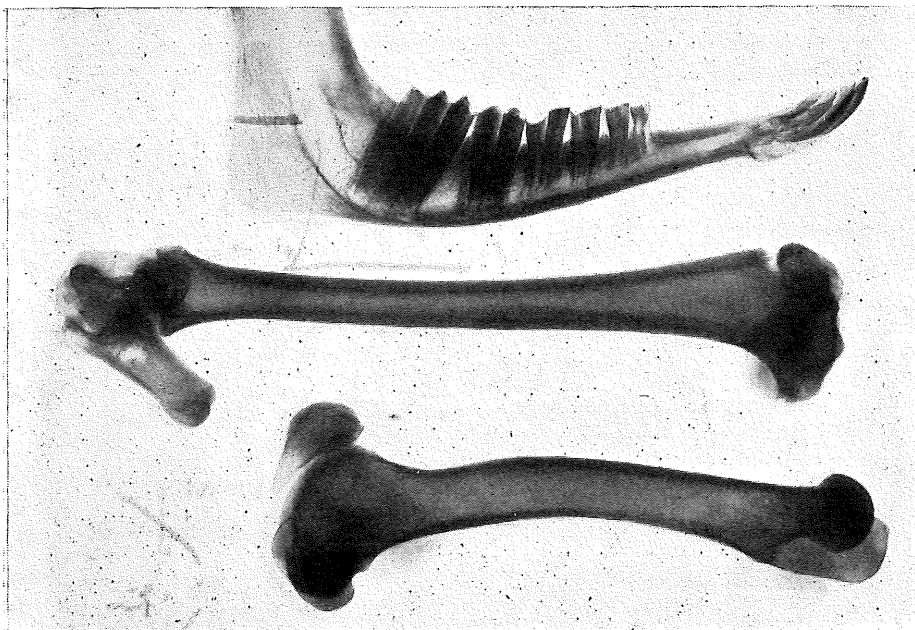


Fig. 8.

Mandible, Femur and Tibia of Sheep from Group 1.

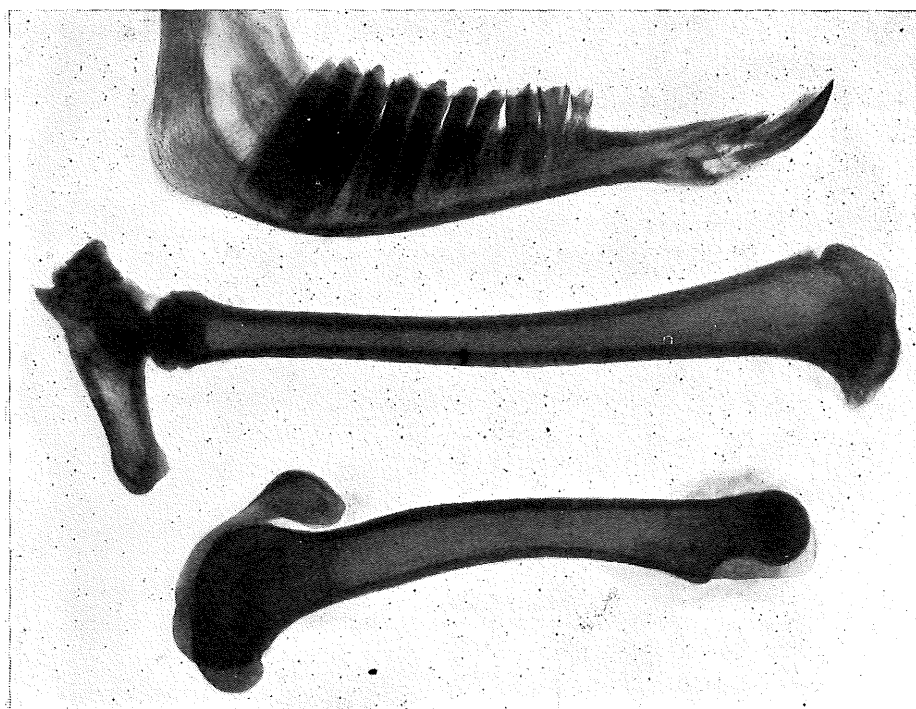


Fig. 9.

Mandible, Femur and Tibia of Sheep from Group 1.

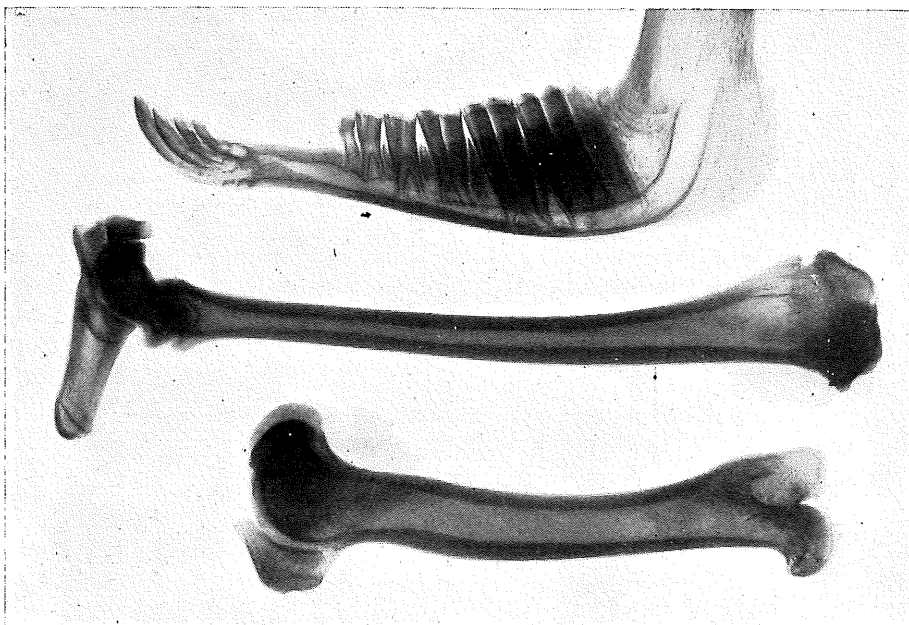


Fig. 10.
Mandible, Femur and Tibia of Sheep from Group 1.

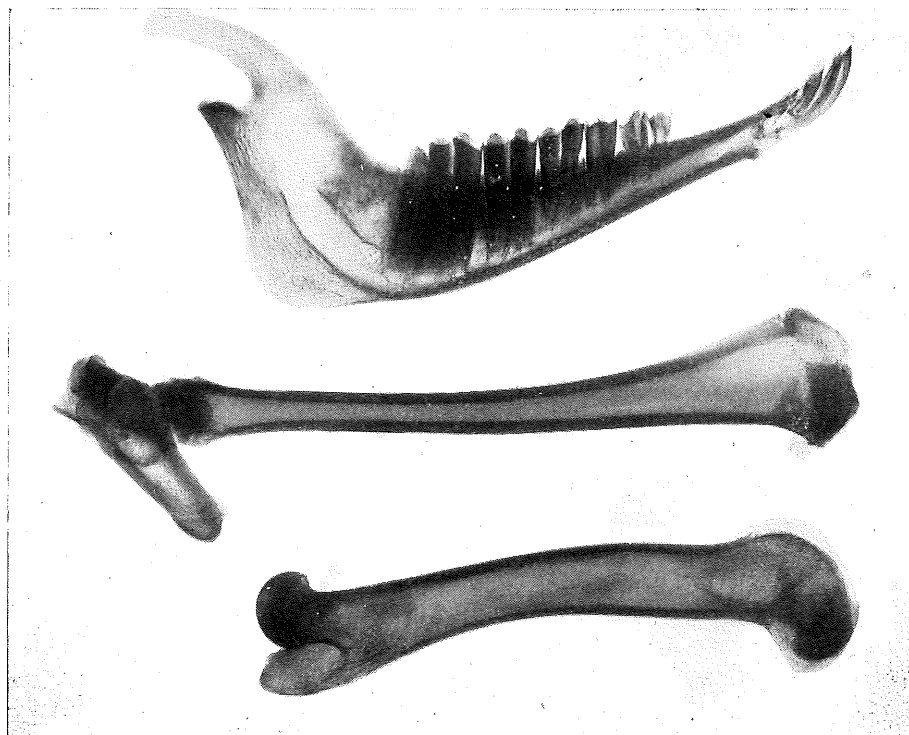


Fig. 11.
Mandible, Femur and Tibia of Sheep from Group 1.

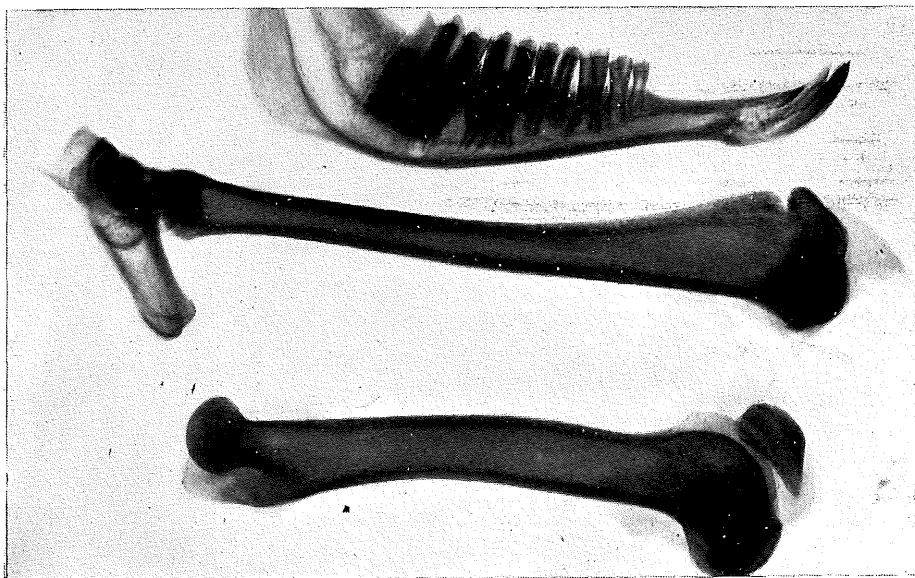


Fig. 12.
Mandible, Femur and Tibia of Sheep from Group 2.

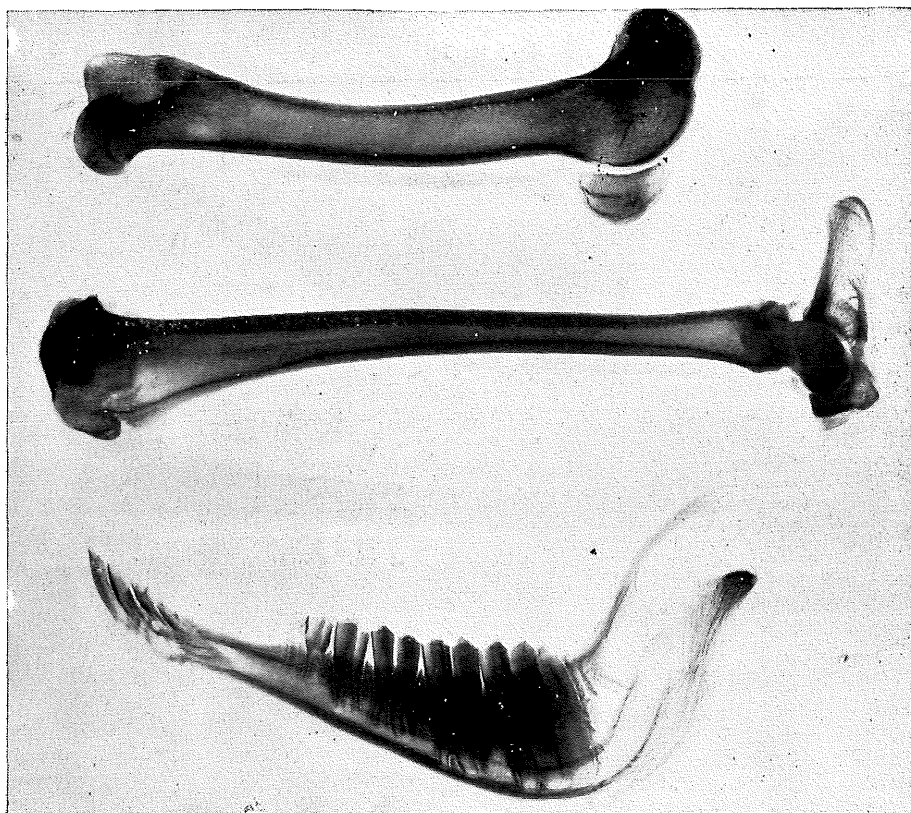


Fig. 13.
Mandible, Femur and Tibia of Sheep from Group 2.

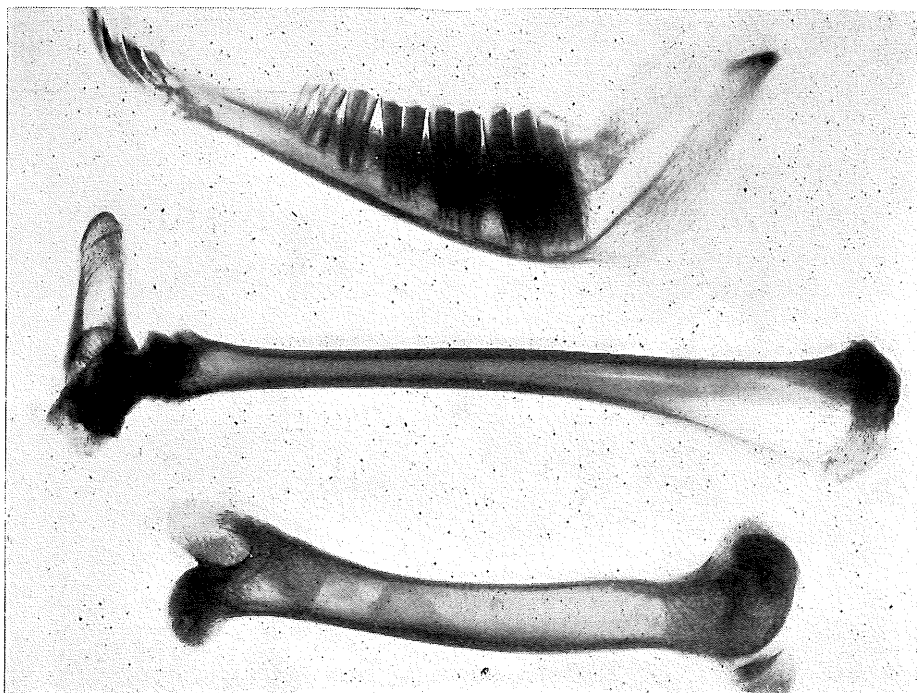


Fig. 14.

Mandible, Femur and Tibia of Sheep from Group 2.

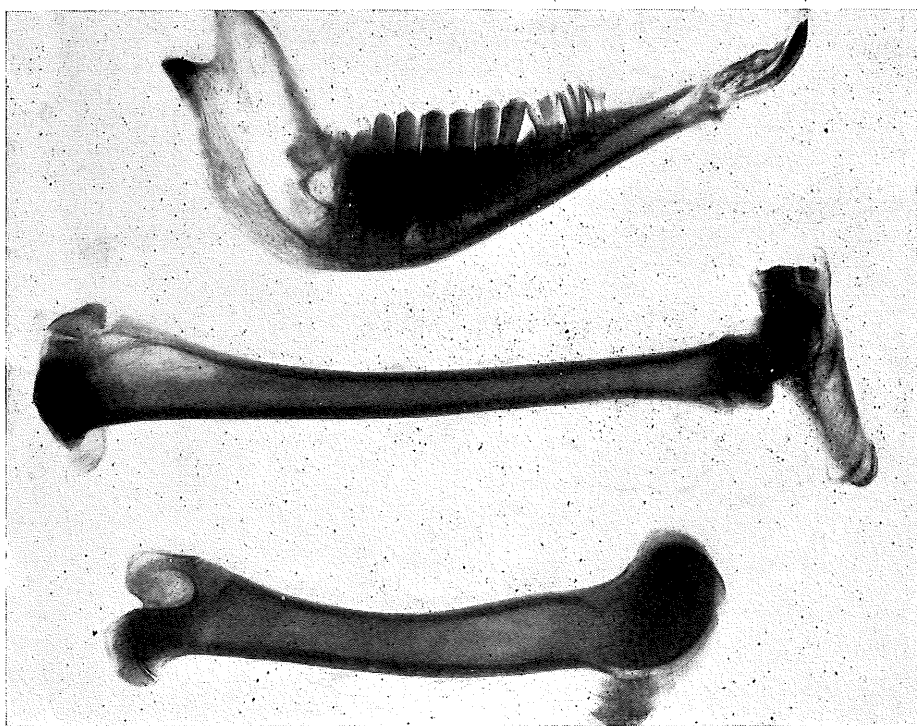


Fig. 15.

Mandible, Femur and Tibia of Sheep from Group 2.

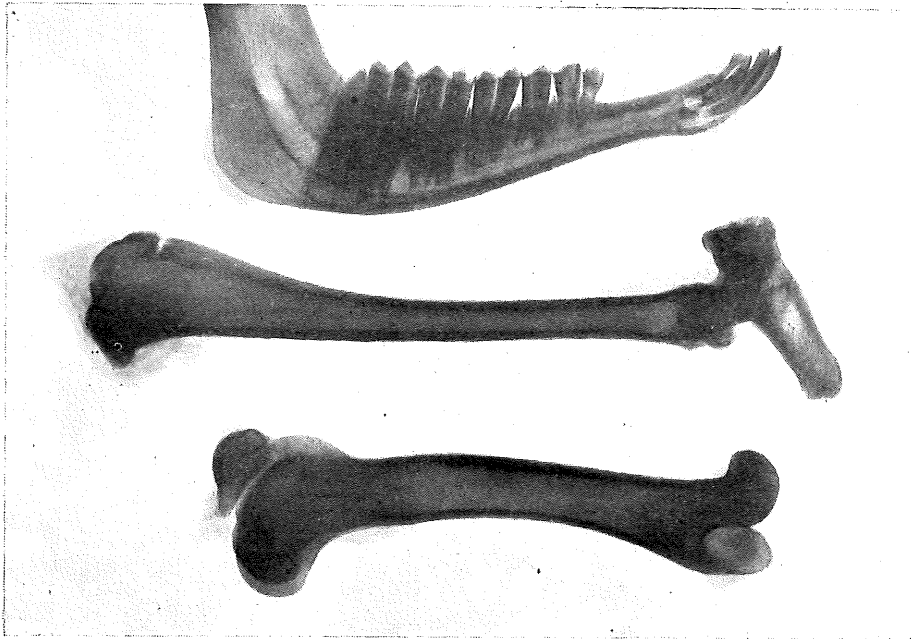


Fig. 16.

Mandible, Femur and Tibia of Sheep from Group 2.

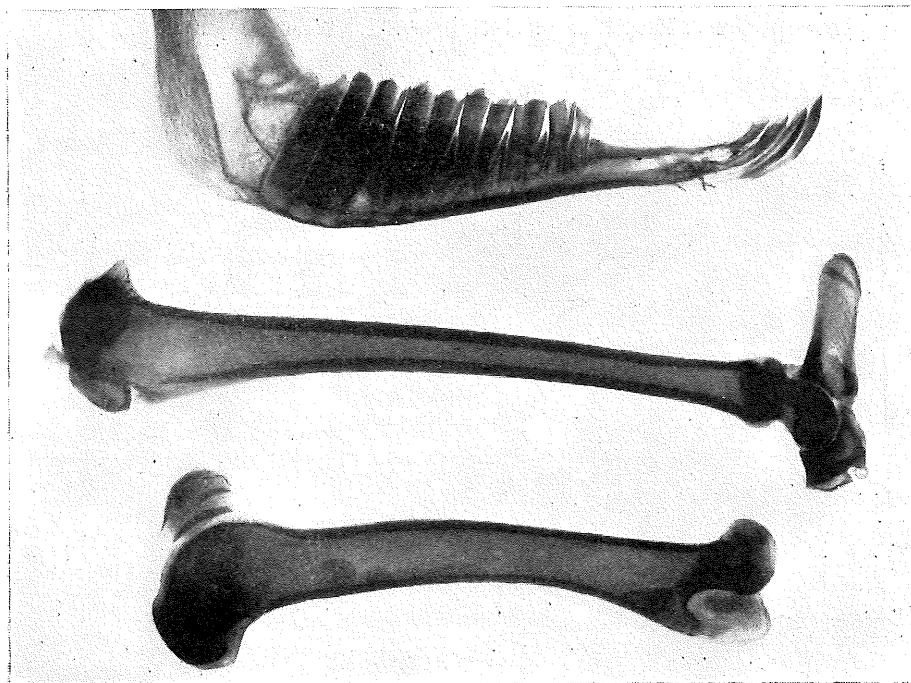


Fig. 17.

Mandible, Femur and Tibia of Sheep from Group 2.

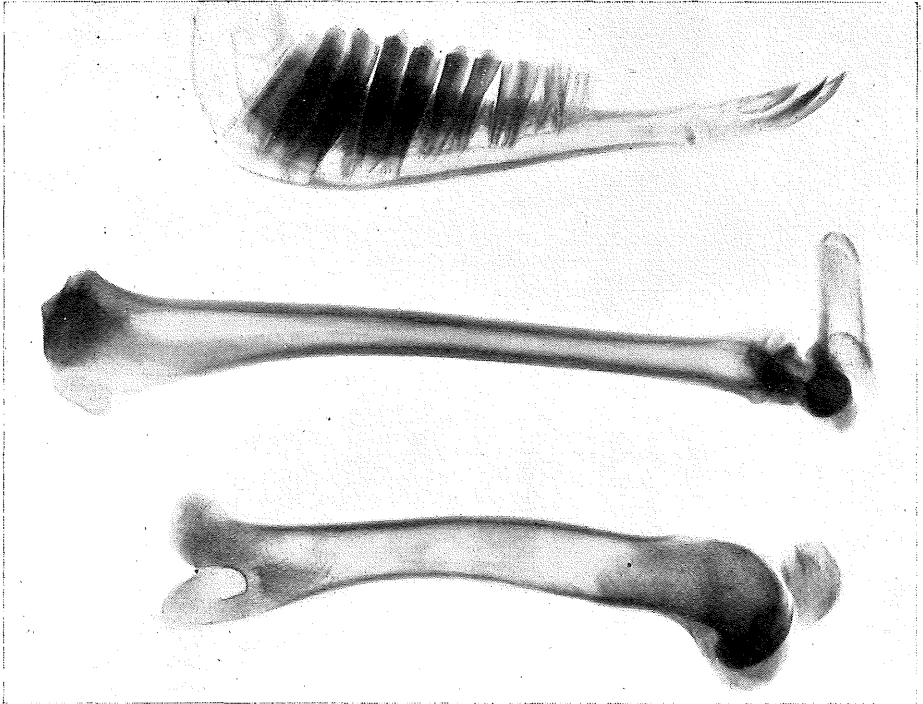


Fig. 18.
Mandible, Femur and Tibia of Sheep from Group 3.

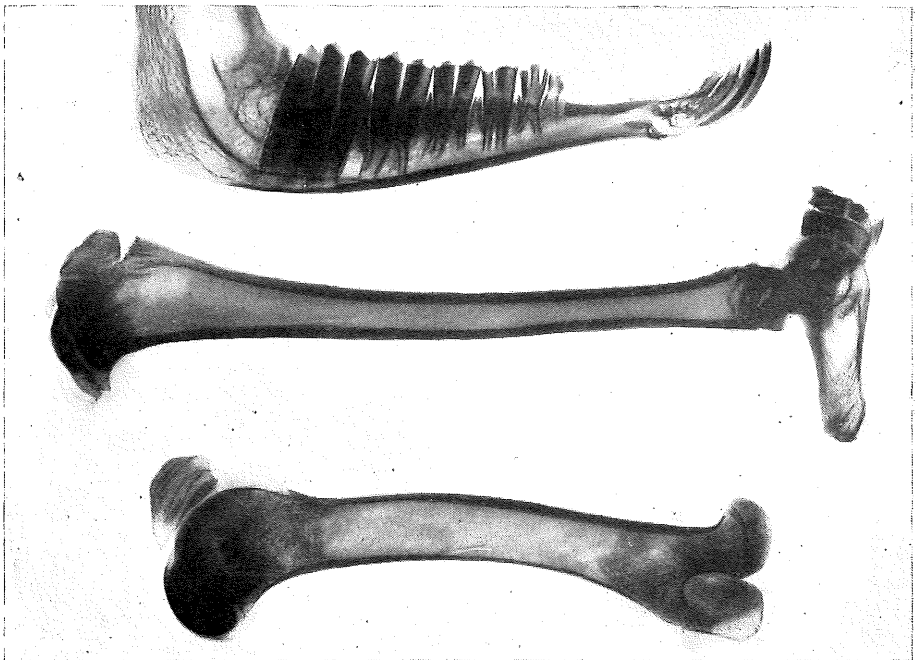


Fig. 19.
Mandible, Femur and Tibia of Sheep from Group 3.

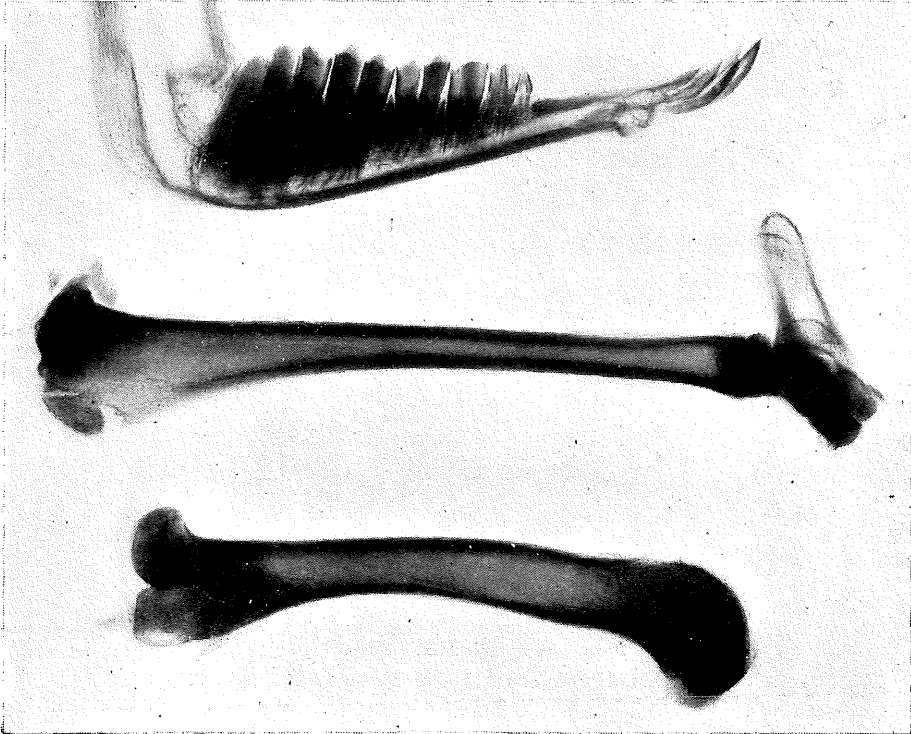


Fig. 20.

Mandible, Femur and Tibia of Sheep from Group 3.

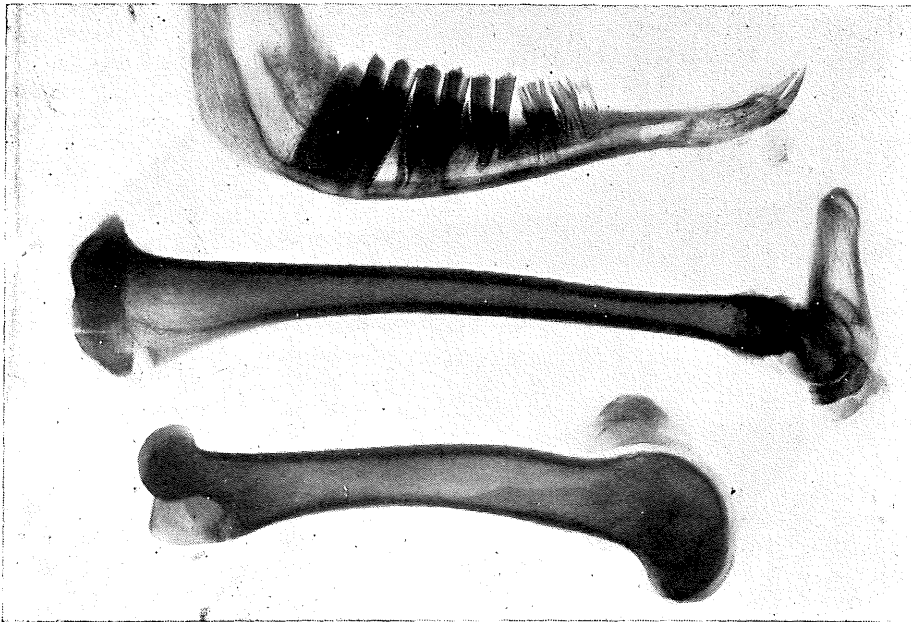


Fig. 21.

Mandible, Femur and Tibia of Sheep from Group 3.

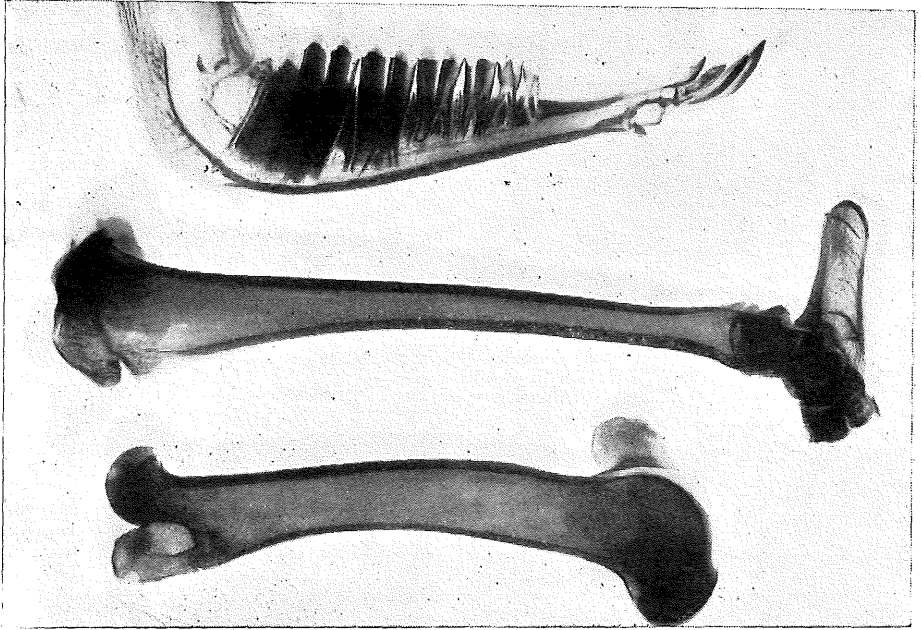


Fig. 22.
Mandible, Femur and Tibia of Sheep from Group 3.

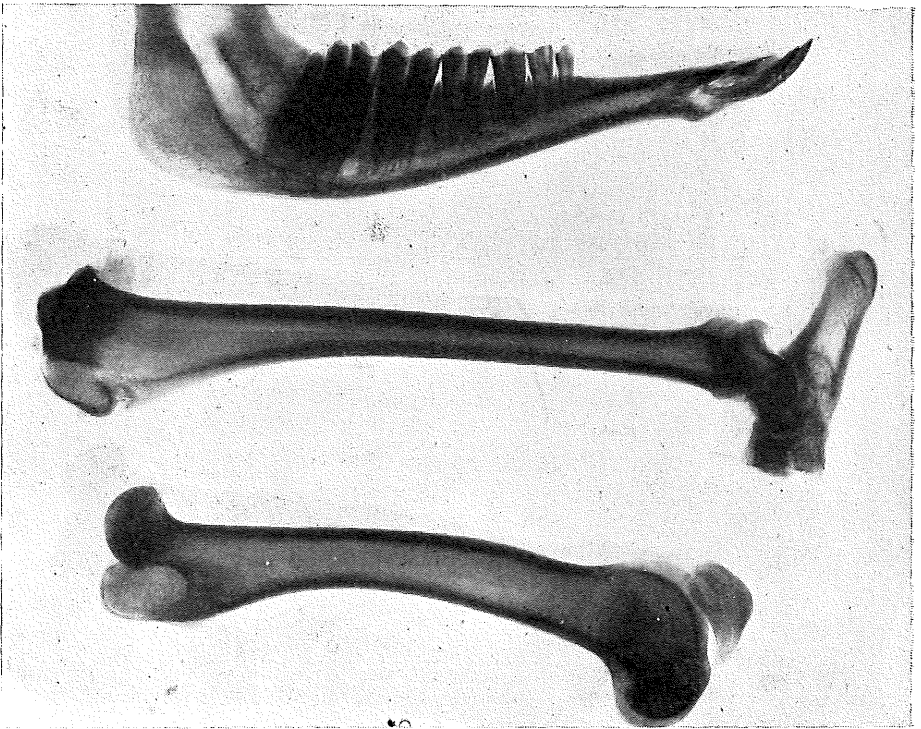


Fig. 23.
Mandible, Femur and Tibia of Sheep from Group 3.

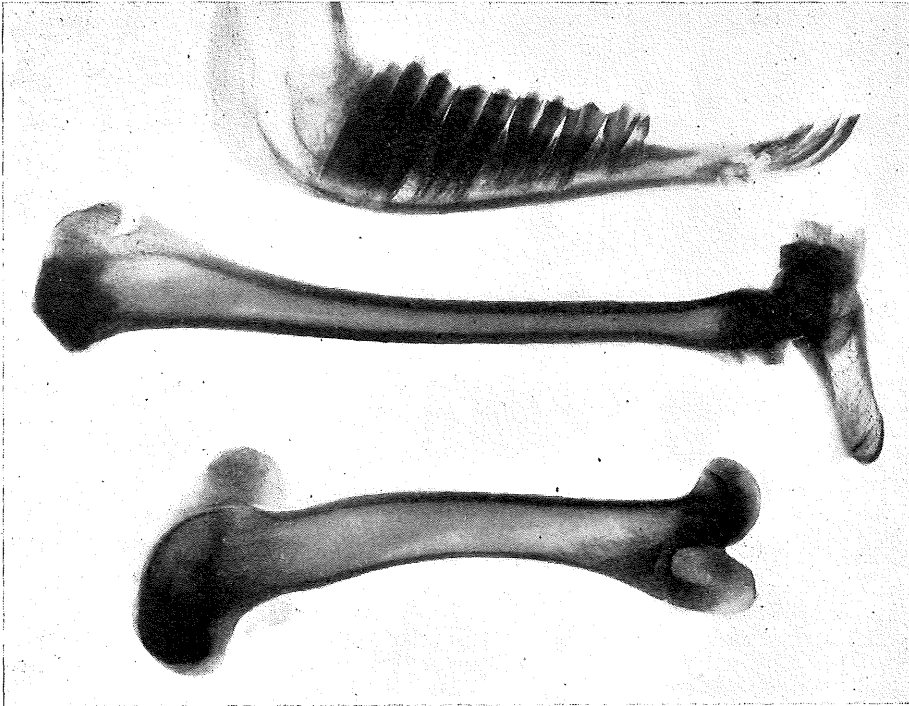


Fig. 24.
Mandible, Femur and Tibia of Sheep from Group 4.

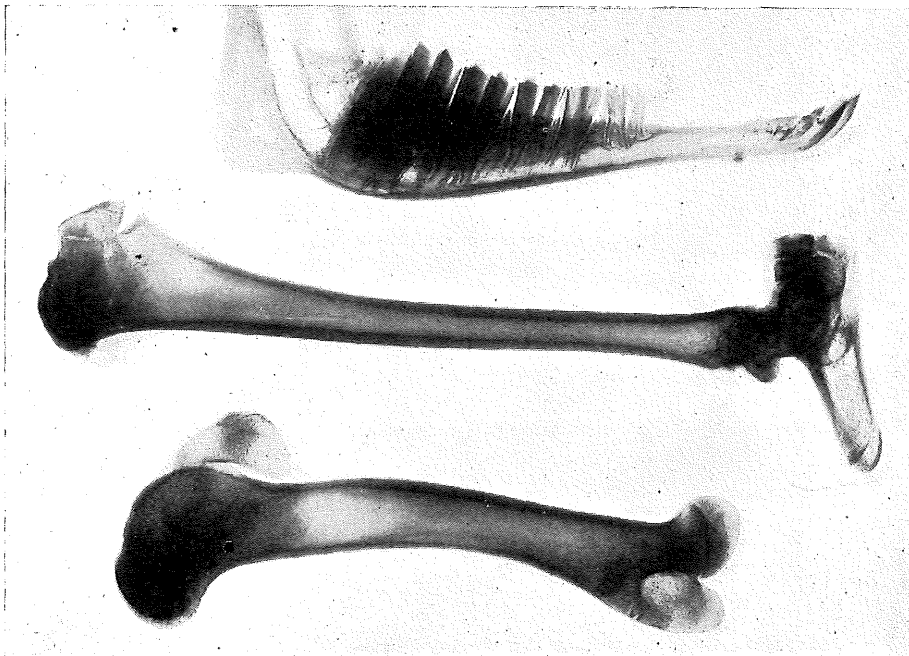


Fig. 25.
Mandible, Femur and Tibia of Sheep from Group 4.

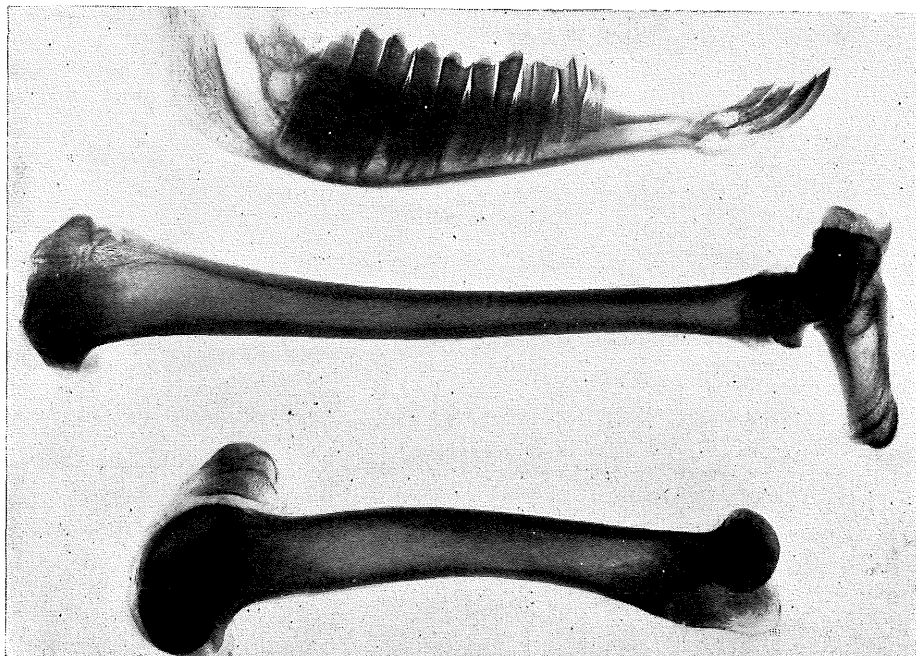


Fig. 26.

Mandible, Femur and Tibia of Sheep from Group 4.

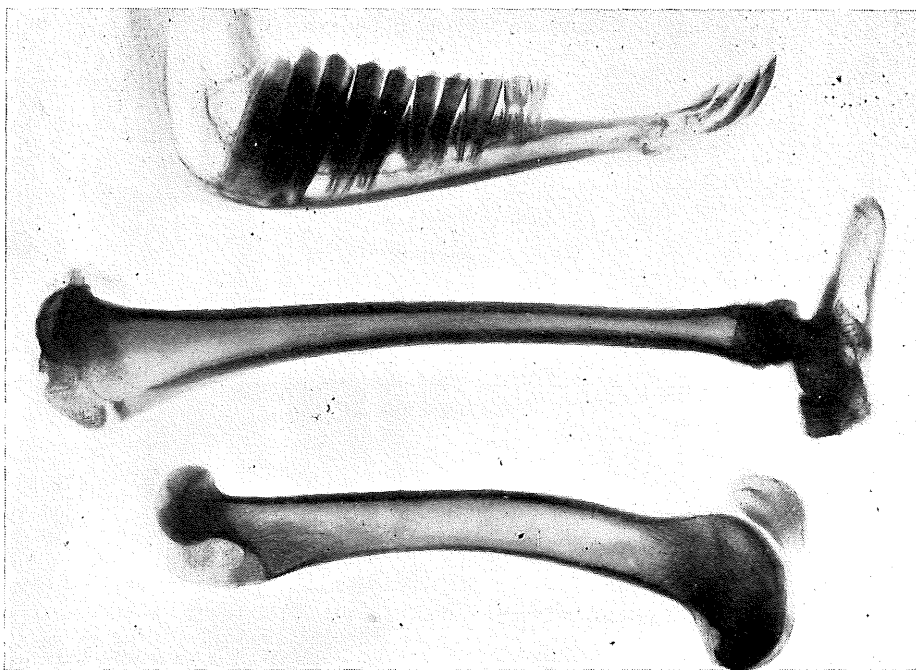


Fig. 27.

Mandible, Femur and Tibia of Sheep from Group 4.

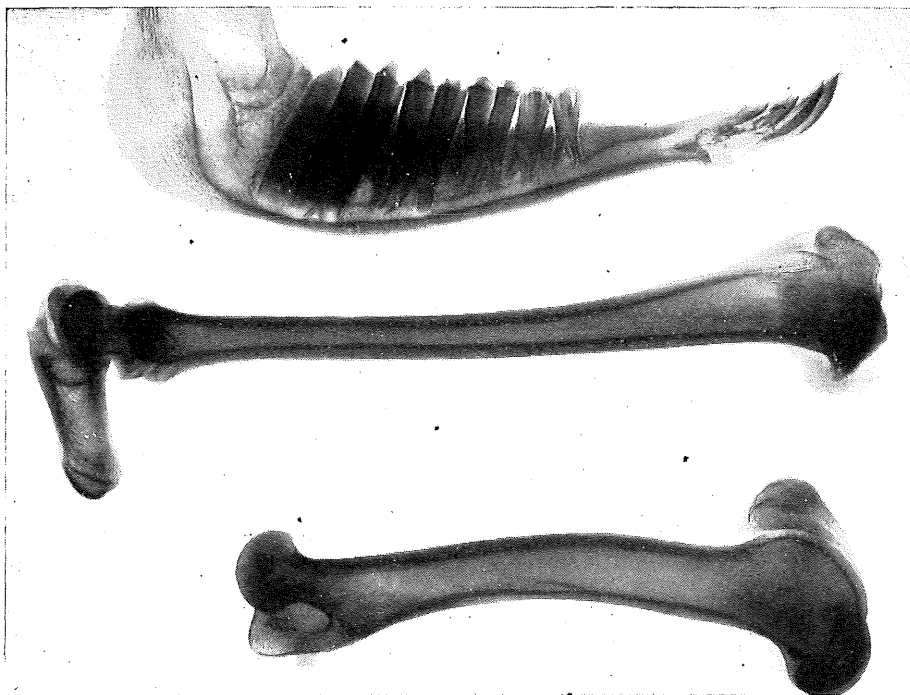


Fig. 28.

Mandible, Femur and Tibia of Sheep from Group 4.

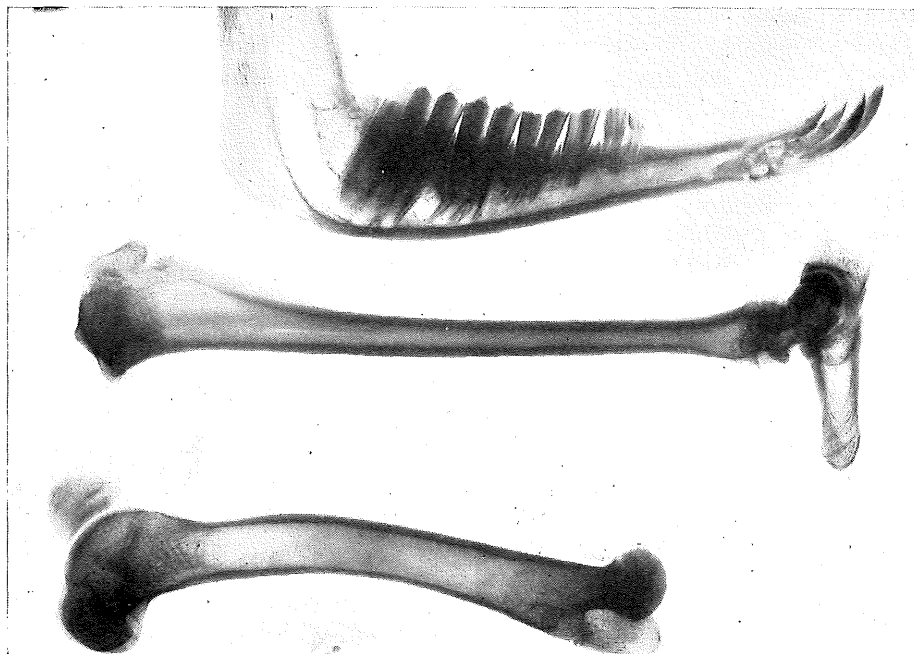


Fig. 29.

Mandible, Femur and Tibia of Sheep from Group 4.

CONCLUSIONS.

Sheep in all groups showed the characteristic fluorotic lesions in the incisor teeth. The damage was most marked in group 1 (continuously exposed to 10 p.p.m.F in the drinking water) and in group 3 (exposed 6 months and protected 3 months). Only in group 2 (exposed 3 months and protected 3 months) were the dental lesions classed as indicating mild fluorosis. There was an indication of uneven wear of molars and premolars in some sheep from all groups other than group 2. The analyses of bones and teeth showed that fluorine storage agreed with these findings. The fluorine concentration in femur, tibia, mandible and teeth was lowest in group 2.

Weight gains and wool growth were similar for all groups. This indicated that up to 30 months' exposure to 10 p.p.m.F in the drinking water did not impair the ability of these animals to gather and masticate grassy lucerne hay of poor quality fed in bales. This is not true for sheep under the same conditions of exposure to fluorine in endemic areas of Queensland—the wear on both incisor and molar teeth is more severe, fractures of the incisors at lines of weakness occur when harsh stubble-like pasture constitutes the bulk of available feed, and production records are unsatisfactory.

Under the experimental conditions, horizontal lines of weakness were apparent in groups 1 and 3, and in two sheep from group 3 fractures of the 1st pair of incisors had occurred. While it might be anticipated that further snapping at lines of weakness would have resulted on continuation of the exposure period, a satisfactory comparison of treatments was possible at the end of 30 months. The treatment most successful in combating the onset of fluorotic lesions was the alternate exposure to and protection from fluorided water for periods of three months.

These findings offer a practical method for the control of endemic fluorosis in Queensland. This control is dependent on either the presence of one or more fluorine-free bores on an affected property or the use of earth tanks or dams for storage of surface water. On the basis of this and previous studies on fluorosis in Merino sheep, recommendations are made for the management of flocks on affected properties.

RECOMMENDATIONS.

(1) Breeding sheep may be held on fluorided water containing up to 10 p.p.m.F. This will not result in an appreciable transmission of fluorine to the lamb, either through foetal circulation or later through the milk.

(2) Either lambs must be weaned early, or ewes and lambs must be transferred to paddocks watered only by fluorine-free water. This transfer must be made before the lambs commence to drink water.

(3) A rotation must be made so that young sheep are protected from fluorided water for a minimum of three months and when exposed do not have access to fluorided water for more than three months.

(4) Sheep over 30 months of age (i.e., when the 3rd pair of incisors are in wear) may be held on paddocks watered by water containing up to 10 p.p.m.F.

As a temporary measure, on properties where no alternative fluorine-free water is available, the harmful effects of fluorine will be minimised if young sheep are watered as near to the borehead as possible. In good or flush seasons, control measures are less important, as the animal will receive the bulk of its fluid requirements from the pasture. These measures afford only a partial relief, and the ultimate control of fluorosis, in areas where all artesian water is affected, involves the storage and economic use of surface water.

ACKNOWLEDGMENTS.

Indebtedness is acknowledged to Dr. John Legg (Director of Research) for housing and feeding facilities for the experimental animals at the Animal Health Station, Yeerongpilly; to Mr. A. K. Sutherland (Senior Veterinary Pathologist) for clinical and post-mortem assistance; to Professor T. K. Ewer and Mr. A. McDowall (Queensland University Veterinary School) for the X-ray photographs; to the late Mr. Thompson (Queensland University Photographer) for photographs of incisor teeth; and to Dr. M. White (Agricultural Chemist of the Department of Agriculture and Stock) for his continuous help and guidance in the course of this study.

REFERENCE.

HARVEY, J. M. 1952. Chronic endemic fluorosis of Merino sheep in Queensland. Qld. J. Agric. Sci. 9: 47-141.
